

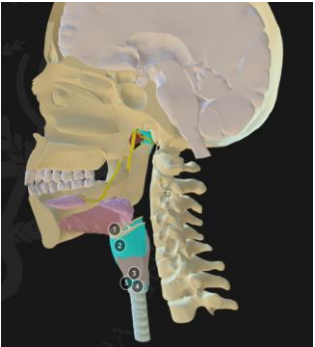


<u>Picture</u>	<u>Name</u>
	<p><u>Hyoid Bone</u></p>
	<p><u>Adolescent Cervical Skeleton and Hyoid</u></p>
	<p><u>Oral Cavity and Hyoid Structures</u></p>